



# DEER HUNTER'S GUIDE for Aging and Jawbone Removal

## SOUTH CAROLINA DEPARTMENT OF NATURAL RESOURCES Big Game Program

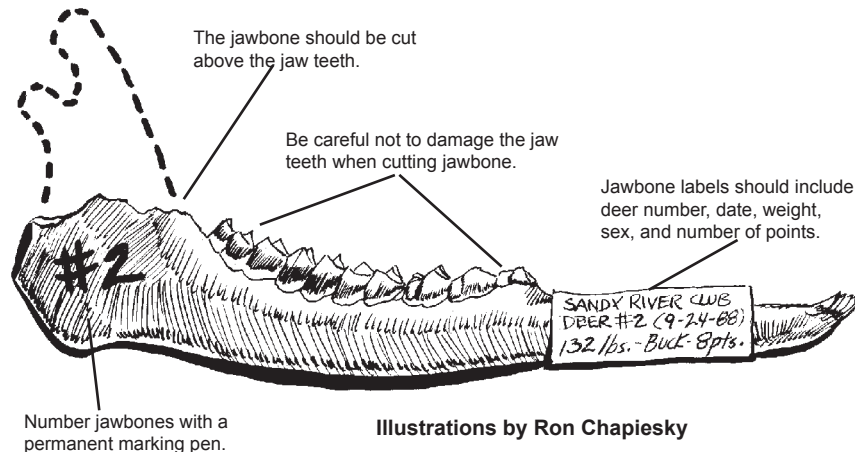
### Here's why:

The success or failure of any deer management program is often measured by the number of deer harvested or more frequently by the size of bucks harvested. One of the most reliable and accurate indicators of management success is deer health.

**Complete and accurate data** collection is essential to monitoring deer health. This brochure describes the technique for removing and labeling deer mandibles (jawbones). A labeled lower jawbone from each harvested deer is an essential part of data collection.

**Wildlife managers determine** the age of deer by jaw tooth replacement and progressive wear. The jaw teeth of white-tailed deer are replaced in a predictable age-related sequence. As an adult, a deer has three premolars and three molars on each side. The loss and replacement of baby teeth follows a predictable schedule. By 17 months of age, the deer's premolars become loose.

Three permanent premolars are fully exposed by 19 months of age. At the same time, the last molars are being cut. After all of the permanent jaw teeth have come in, age determination is made by examining the amount of wear on the molars.



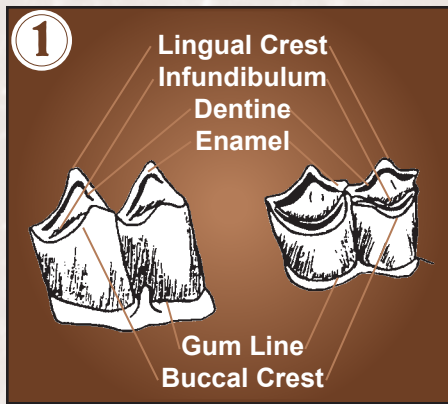
Illustrations by Ron Chapiesky

Once the age of the animal is **determined** by examining the lower jawbone, the corresponding weight for bucks and does is used to determine deer health and condition. Buck antler development is also used to determine deer health and condition. Years of research throughout the country have determined expected or potential weights for each age class of deer. Data collection allows wildlife managers to determine the ideal weight and condition of a yearling (1½ years old) buck in good condition by combining the techniques described. Without a corresponding age, weight and antler development information is practically useless. A six-point buck weighing 130 pounds could be an excellent 1½ years old or a poor 3½ years old. Over time, data comparisons allow the manager to determine harvest recommendations in response to changes in herd health indicators.

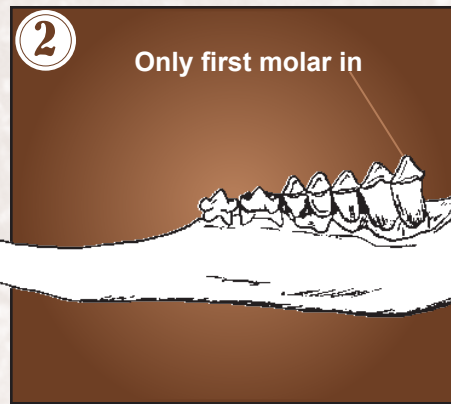
*Continued on back page*

### FOR ADDITIONAL INFORMATION

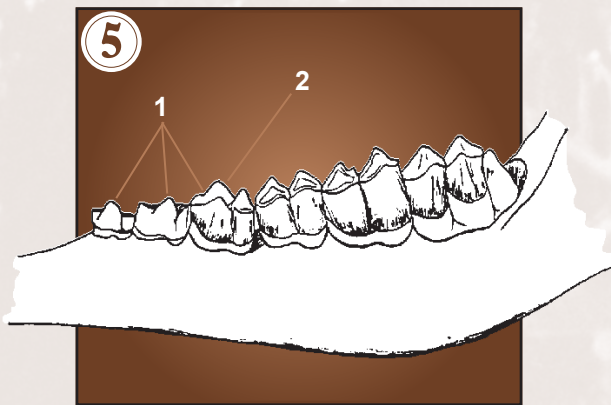
concerning the Deer Management Program contact your regional wildlife biologist or the South Carolina Department of Natural Resources in Columbia at (803) 734-3886 or visit our website at [www.dnr.sc.gov](http://www.dnr.sc.gov).



**JAW TEETH**

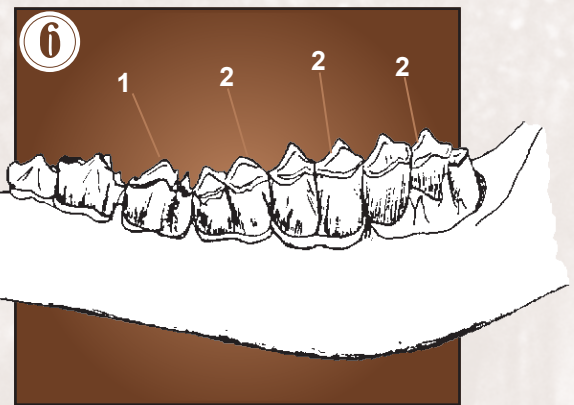


**6 MONTHS**



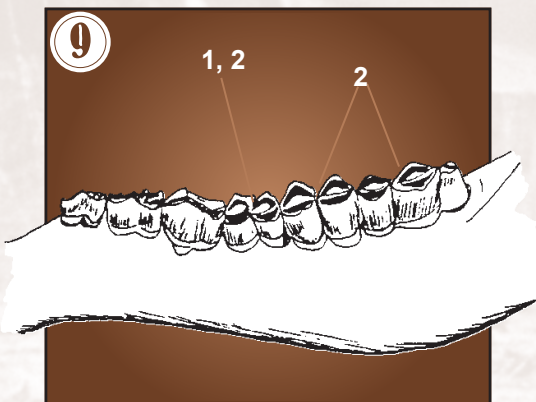
**1 YEAR and 7 MONTHS**

1. All permanent premolars are fully erupted and show light staining.
2. There is no, or only a very fine, dentine line on crest of the third premolar.



**2 ½ YEARS**

1. Obvious, but not severe, dentine line on third premolar.
2. Dentine relative to enamel of lingual crest equal on first molar, narrower on second and third molars.



**5 ½ YEARS**

1. Dentine relative to enamel wider on all molars.
2. Secondary crest of first molar severely worn but still visibly raised on both cusps.

## EXAMPLES OF WHITE-TAILED DEER TOOTH RE

Drawings by Mary Elizabeth Ferdon, Bell Baruch Forest Science Institut

Determining the exact age of an adult deer can be difficult and requires much separate deer into classes of fawns, yearlings (1½ years) and adults. Using yearling (1½ years old) or an adult (2½ years or older).

After removing and cleaning the jaw bone (see back cover), count the number

If the jaw bone has fewer than 6 jaw teeth it is a fawn. (See figure 2.)

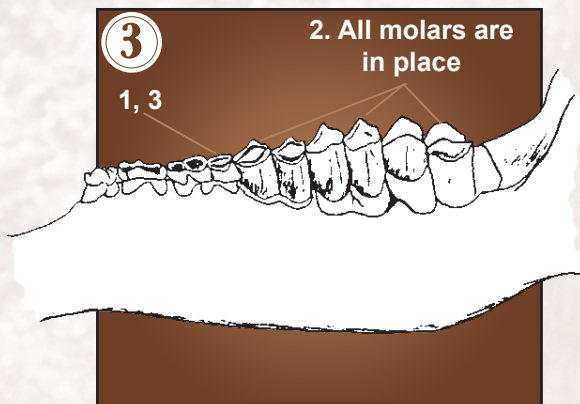
If the jaw bone has 6 jaw teeth, the deer is 1½ years or older. (See figure 4.)

To determine whether a deer is 1½ years or older, examine the third premolar

old. In some cases, you will notice that the third premolar has just been replaced may not be fully erupted. You may also notice that other premolars are being age class.

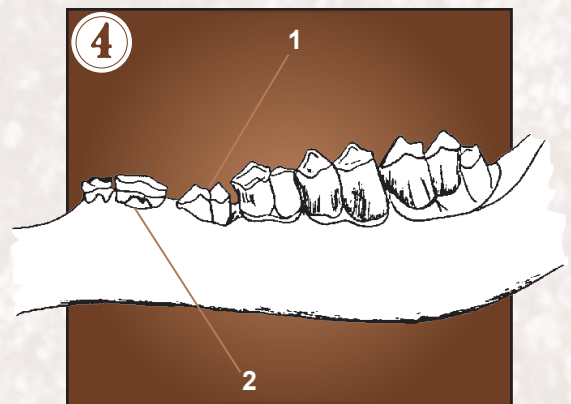
If the jaw bone contains the adult (bicuspid) third premolar that shows staining and some wear then the deer must be at least 2½ years old or older. (See figures 6 through 9.)





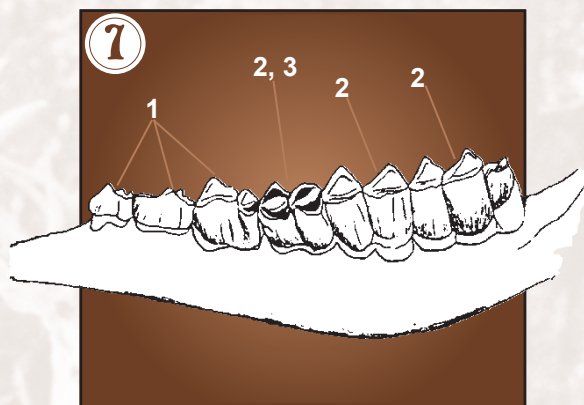
### 1 YEAR and 5 MONTHS

1. Third premolar, known as the tricuspid, has 3 cusps but heavily worn.
2. All molars in place.
3. All temporary premolars are in place.



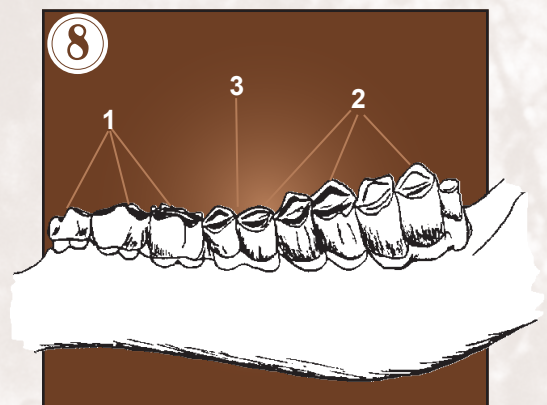
### 1 ½ YEARS

1. At least one temporary premolar has been shed.
2. Permanent premolar with two cusps, known as the bicuspid, is erupting.



### 3 ½ YEARS

1. All premolars show considerable wear; second cusp of third premolar worn smooth or into a cupped appearance.
  2. Dentine relative to enamel wider on first molar, equal on second, narrower on third.
  3. Secondary crest of first molar well raised.
- NOTE: Do not use premolars after 3½ years.



### 4 ½ YEARS

1. All premolars severely worn.
2. Dentine relative to enamel is wider on first and second molars and equal on third.
3. Secondary crest on first molar well worn but still moderately raised.

## REPLACEMENT AND WEAR

ate of Clemson

h experience. However, for management purposes, it is effective and easy to the quick steps listed below, you can determine whether the deer is a fawn, a

er of jaw teeth.

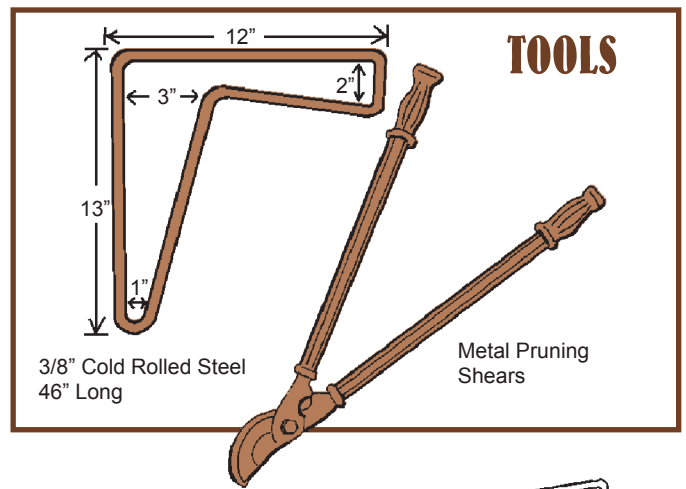
ar. If the third premolar is a tricuspid (three part tooth), then the deer is 1½ years

aced by a bicuspid (two part tooth). The bicuspid will be very clean and white and g replaced by new teeth from below. This deer is still in the 1½ year

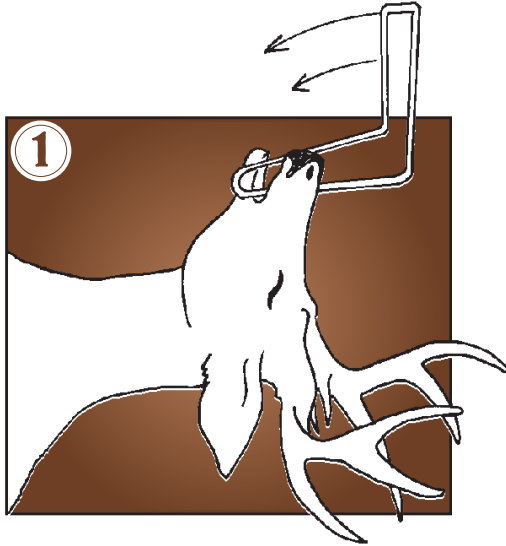


## Here's how:

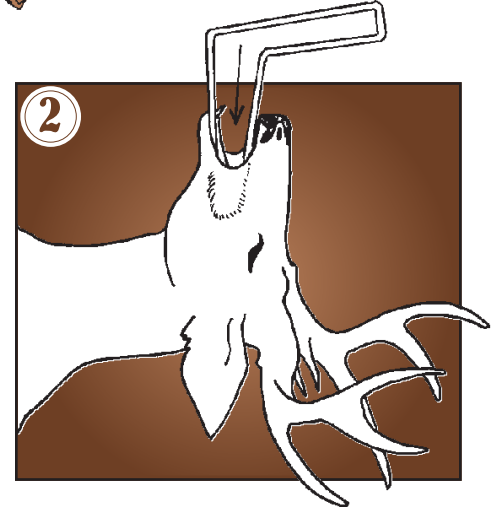
For proper jawbone extraction, you must have two essential tools. (See illustration at right.) The first is a jaw opener-extractor made from a 46-inch length of 3/8-inch cold rolled steel. In addition, the hunter should have pruning shears like the ones that are used for cutting shrubbery and small tree limbs.



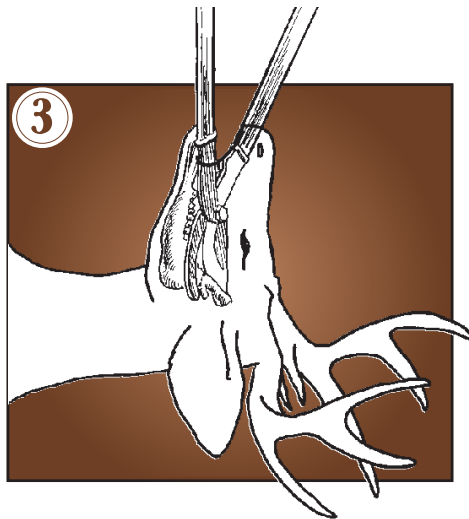
1. Place the back of the deer's head on a flat surface and open the deer's mouth by inserting the small end of the jaw opener from the side of the deer's mouth between the front teeth (incisors) and the first jaw teeth (premolars). Rotate the tool 90 degrees to open the mouth.



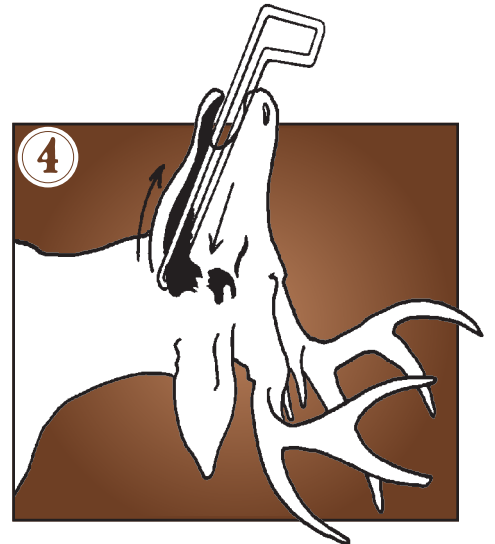
2. Insert the jaw opener between the cheek and jawbone. Push the jaw opener downward toward the base of the jaw to free the skin and muscle attached to the lower jaw along gumline.



3. Insert the closed pruning shears into the deer's mouth with the curve of the blade facing inward. Open the shears and place the cutter bar behind the last jaw teeth (molars) on the outside of the jawbone. Place the handles of the shears parallel to the roof of the animal's mouth and cut the bone and muscles. Be careful not to break the jaw teeth.



4. Remove the shears and push the small end of the jaw opener-extractor through the cut made in step 3. Place one foot on the deer's neck, antlers or ear and pull the tool out of the deer's mouth, causing the tool to slide along the underside of the jawbone, removing the muscles. The jawbone will separate between the incisors and can be lifted out. If the crests of the jaw teeth are malformed or broken, age determination may be impossible. If the jaw teeth are malformed or broken, carefully remove the other jawbone to determine age. The jawbones can be attached together and appropriately labeled.



5. Jawbones can be cleaned by simply dropping them on the ground and vigorously rubbing each side with your foot, followed by wiping them with a cloth. Number each jawbone with a permanent marker. The number assigned to each jawbone should correspond with the deer number that appears on the data sheet or card. Some managers prefer to attach a label to each jawbone with the deer number, date, weight, sex and number of points. Jawbones should be stored away from scavengers and allowed to air dry. A wire cage, fish basket or ventilated wooden crate works well when used in an outbuilding or garage. A few moth balls will prevent insect problems. Freezing, refrigerating or storing jawbones in plastic bags will cause offensive odors and labels may become illegible.

**CAREFUL REMOVAL OF THE JAW DOES NOT  
DAMAGE THE DEER HEAD FOR MOUNTING.**

