


**DEPARTMENT OF HEALTH AND HUMAN SERVICES
OFFICE OF DIRECTOR**

ACTION REFERRAL

TO <i>Mjyas</i>	DATE <i>3-4-09</i>
-------------------------------	----------------------------------

DIRECTOR'S USE ONLY		ACTION REQUESTED	
1. LOG NUMBER <i>100483</i>	<input type="checkbox"/> Prepare reply for the Director's signature DATE DUE _____		
2. DATE SIGNED BY DIRECTOR <i>Cleared 3/12/09, letter attached.</i> 	<input checked="" type="checkbox"/> Prepare reply for appropriate signature DATE DUE <i>3-13-09</i> _____ <input type="checkbox"/> FOIA DATE DUE _____ <input type="checkbox"/> Necessary Action		

APPROVALS <small>(Only when prepared for director's signature)</small>	APPROVE	* DISAPPROVE <small>(Note reason for disapproval and return to preparer.)</small>	COMMENT
1.			
2.			
3.			
4.			

COASTAL SURGICAL VASCULAR & VEIN SPECIALISTS

Edward C. Morrison, M.D.
General & Vascular Surgery
Board Certified

Thomas C. Appleby, M.D.
General & Vascular Surgery
Board Certified

P. Kevin Beach, M.D.
General & Vascular Surgery
Board Certified

March 2, 2009

RECEIVED

Mar 04 2009

Dr. Marion Burton
Medical Director
S.C. Dept of Health & Human Services
P. O. Box 8206
Columbia, S.C. 29202-8206

Department of Health & Human Services
OFFICE OF THE DIRECTOR

Re: Linda Brown
ID# 5780472700

Dear Dr. Burton,

Ms. Linda Brown was initially seen by me on 8/26/08 for evaluation of bilateral pain in the lower extremities. She is symptomatic with swelling and numbness. A bilateral lower extremity venous ultrasound performed on 9/18/08 revealed reflux disease bilaterally. She was given a prescription for compression stockings on 8/26/08. She underwent endovenous ablation of the right lower extremity on February 3, 2009 which has shown great results. I believe that it would benefit her to treat the left lower extremity. A copy of my recent office note and venous study are attached.

We would appreciate your consideration of this service based on the above and attached information. This surgery is not typically a covered service by Medicaid. The CPT code is 36475.

We will await your response. Please feel free to contact me with any questions.

Sincerely,

Edward C. Morrison M.D.
Edward C. Morrison, M.D.

Moncks Corner
2061 Highway 52

Mt. Pleasant
570 Longpoint Rd., Suite 130

1327 Ashley River Rd., Bldg. B
Charleston, SC 29407
Telephone (843) 577-4551
Fax (843) 577-8868

Walterboro
416 B Robertson Blvd.

ACCOUNT # 15911
LINDA BROWN
02/26/09

843-509-3666

02/29/1950

Address: 8029456

BP

BROWN, Linda P. 73911

Brandy Englert, PA-C

PULSE

02/26/2009

TEMP

ALLERGIC

The patient was seen today for follow up of her lower extremity pain and venous stasis disease. The patient states that since her right VNUS Closure was done, she has had much improvement in her right lower extremity. She states that the pain and swelling have improved tremendously. ~~The patient denies any new complaints. The patient states that her left leg is problematic and she would like this leg treated as well. The patient is still ambulating with a walker.~~

PHYSICAL EXAM: The patient is alert and oriented and in no acute distress. Neck is soft and supple and without bruits. Heart is regular rate and rhythm and lungs are clear. The patient has a known systolic ejection murmur. The patient's lower extremities are edematous and there are superficial varicosities bilaterally. There is no new skin breakdown. Feet are warm with palpable peripheral pulses. The patient's toes remain cyanotic.

DATA: I have reviewed the results of this patient's ABIs which were done today, which are within normal limits. I have also reviewed the results of her vascular ultrasound which showed successful closure of her right greater saphenous vein.

IMPRESSION:

1. Venous stasis disease
2. Mild peripheral vascular disease

PLAN: The patient certainly has great results from her right VNUS Closure. The patient's conservative therapy has to date been unsuccessful in either leg and thus, I believe it would be beneficial to be treated for her left lower extremity. I will get her scheduled to have a left VNUS Closure done at our next available appointment. BRANDY ENGLERT, PA-C/hma

cc Dr. Browder

CVE
Systems

17207 Wyeth Circle, Spring Texas 77379

Phone: 800-338-0360 Email: Support@cvesystems.com

CVE Systems

Coastal Surgical Associates

1327 Ashley River Road

Charleston, SC 29407

843-577-4551 Fax: 843-577-8868

Lower Venous Duplex Scan

Patient Name: BROWN, LINDA Study Date: 9/18/2008 Time: 12:36:49 PM
DOB: 7/29/1950 Age: 58 Gender: Female MR/Case#: 73911
Referring Phy: EDWARD C. MORRISON, MD Lab: COASTAL SURGICAL ASSOCIATES
Indication: BILATERAL LEG NUMBNESS/BURNING Examiner: Tosti, Liberty, RVT

CONCLUSION/SUMMARY:

NEGATIVE EXAM FOR DEEP OR SUPERFICIAL VEIN THROMBOSIS BILATERALLY.

THE RIGHT LOWER EXTREMITY IS ~~POSITIVE~~ FOR DEEP AND SUPERFICIAL VEIN THROMBOSIS AS DESCRIBED WITH SUFFICIENT GSV AND ANTERIOR ACCESSORY VEIN DIAMETERS IF CLOSURE IS CONSIDERED.

THE LEFT LOWER EXTREMITY IS ~~POSITIVE~~ FOR DEEP AND SUPERFICIAL VEIN THROMBOSIS AS DESCRIBED WITH SUFFICIENT GSV DIAMETERS IF CLOSURE IS CONSIDERED.

Thermon 9.19.08
Date



CVE Systems

17207 Wyeth Circle, Spring Texas 77379

Phone: 800-338-0360 Email: Support@cvesystems.com

Coastal Surgical Associates

1327 Ashley River Road

Charleston, SC 29407

843-577-4551 Fax: 843-577-8868

Lower Venous Duplex Scan

Patient Name: BROWN, LINDA

Study Date: 9/18/2008

Time: 12:36:49 PM

DOB: 7/29/1950 Age: 58 Gender: Female

MR/Case#: 73911

Referring Phy: EDWARD C. MORRISON, MD

Lab: COASTAL SURGICAL ASSOCIATES

Indication: BILATERAL LEG NUMBNESS/BURNING

Examiner: Posti, Liberty, RVT

HISTORY:

DIABETIC RETINOPATHY, DIABETES, CRF ON DIALYSIS, LEFT UPPER ARM DIALYSIS FISTULA, HIGH CHOLESTEROL, DJD, HTN, CHF, HYPOTHYROIDISM, HIP AND PELVIC FRACTURES, RIGHT ANKLE FRACTURE IN 2008, LEFT ANKLE FRACTURE 20 YEARS AGO.

INDICATION:

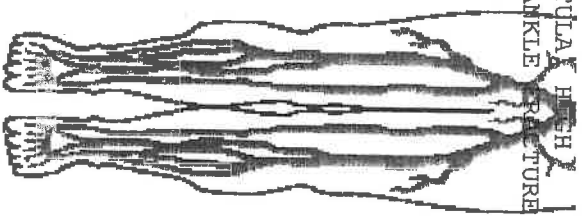
BILATERAL LEG NUMBNESS, PAIN AND BURNING, LT > RT; CVI.

TECHNOLOGIST NOTES:

Summary of Vascular Findings

Impression/Recommendation:

BILATERAL LOWER EXTREMITY VENOUS DUPLEX EXAMINATION OF THE DEEP FEMORAL SYSTEM, POPLITEAL, POSTERIOR TIBIALS, PERFORATORS AND GSV COMPLETED WITH THE FOLLOWING FINDINGS:



RIGHT:

NEGATIVE EXAM FOR DEEP AND SUPERFICIAL VEIN THROMBOSIS. REFLUX WAS DEMONSTRATED IN THE FEMORAL SYSTEM, GSV, ANTERIOR ACCESSORY VEIN AND ANKLE PERFORATOR VEIN MEASURING 0.25CM. THE GSV MEASURED: JUNCTION 0.38CM, PROXIMAL THIGH 0.39CM, MID 0.34CM, DISTAL THIGH 0.37CM, PROXIMAL CALF 0.32CM, MID CALF 0.30CM. THE ANTERIOR ACCESSORY VEIN MEASURES: JUNCTION 0.57CM, PROXIMAL THIGH 0.51CM, MID 0.49CM, DISTAL THIGH 0.40CM. A BRANCH FROM THE GSV AND ACCESSORY VEIN CONNECT AT THE MEDIAL KNEE LEVEL. MULTIPLE BRANCHES WERE NOTED FROM THE GSV AND ANTERIOR ACCESSORY VEIN ABOVE AND BELOW THE KNEE.

LEFT:

NEGATIVE EXAM FOR DEEP AND SUPERFICIAL VEIN THROMBOSIS. REFLUX WAS DEMONSTRATED IN THE FEMORAL SYSTEM AND BELOW-KNEE GSV. THE GSV TRAVELS POSTERIORLY WITH A MID-THIGH LEVEL BRANCH FOLLOWING THE SAME COURSE SUPERFICIALLY. THE GSV MEASURES: JUNCTION 0.42CM, PROXIMAL THIGH 0.47CM, MID 0.27CM (BRANCH TAKES OFF), DISTAL 0.33CM, PROXIMAL CALF 0.28CM AND MID CALF 0.25CM. THE ANTERIOR ACCESSORY VEIN DOES NOT SHOW REFLUX. MULTIPLE BRANCHES WERE NOTED FROM THE GSV AND ANTERIOR ACCESSORY VEIN ABOVE AND BELOW THE KNEE.

483



State of South Carolina
Department of Health and Human Services

Mark Sanford
Governor

Emma Forkner
Director

March 12, 2009

Edward C. Morrison, M.D.
Coastal Surgical Vascular & Vein Specialists
1327 Ashley River Road, Bldg. B
Charleston, SC 29407

Re: Linda Brown
ID# 5780472700

Dear Dr. Morrison,

Thank you for corresponding regarding this patient. I agree that the endovenous ablation of the left lower extremity is certainly clinically indicated in this case. Please submit a copy of this letter with your request for payment for this procedure. If you have any further difficulty, please contact me at 803-255-3400 or 803-898-2580.

Thank you for your advocacy regarding this patient and for caring for South Carolina Medicaid beneficiaries.

Sincerely,

A handwritten signature in cursive script, reading "O. Marion Burton".

O. Marion Burton, M.D.
Medical Director